Management of Biological Invasions (2019) Volume 10, Issue 2: 285–295

Rapid Communication

Ligation and division of *ductus deferens* does not produce long term sterility in most bighead carp or grass carp

Duane C. Chapman[1,*], Marco Milardi[2] and F.A. Mann[3]

[1]*U.S. Geological Survey, Columbia Environmental Research Center, Columbia, MO, USA*
[2]*Department of Life Sciences and Biotechnology, University of Ferrara, Ferrara, Italy*
[3]*Veterinary Health Center, University of Missouri, Columbia, MO, USA*

Author e-mails: *dchapman@usgs.gov (DCC), marco.milardi@gmail.com (MM), mannF@missouri.edu (FAM)*

**Corresponding author*

Citation: Chapman DC, Milardi M, Mann FA (2019) Ligation and division of *ductus deferens* does not produce long term sterility in most bighead carp or grass carp. *Management of Biological Invasions* 10(2): 285–295, https://doi.org/10.3391/mbi.2019.10.2.05

Received: 5 June 2018

Accepted: 24 January 2019

Published: 29 April 2019

Thematic editor: Matthew Barnes

Abstract

Invading species are most easily eradicated or controlled if detected early and rapid action can be taken, but locating and eradicating small numbers of aquatic invaders is extremely difficult. Bighead carp (*Hypophthalmichthys nobilis*) and grass carp (*Ctenopharyngodon idella*) are Asian cyprinids that have been widely introduced and are considered undesirable and detrimental invasive species in many parts of their introduced range. The relatively novel "Judas fish" technique is used to locate aggregations of fish in the wild by strategically releasing individuals equipped with surgically implanted transmitters. However, releasing Judas fish that are capable of reproducing is problematic because it could add to the invasion problem by contributing to recruitment if not recaptured. We thus tested whether surgical ligation and division of the *ductus deferens* could effectively sterilize adult diploid bighead and grass carp. If effective, surgical sterilization would result in a superior Judas fish by maintaining the reproductive motivation derived from intact gonads while blocking the reproductive potential. This technique was initially successful, but ultimately most individuals were able to recanalize the surgically-severed ducts and produce milt, and were thus potentially able to reproduce during the following spawning season. Thus, ligation and division of the ductus deferens does not seem to be a viable procedure to sterilize bighead carp or grass carp for deployment as Judas fish where long term sterility of the fish is paramount in importance.

Key words: Asian carps, invasive species, Judas fish, telemetry, fish surgery, sterile fish

Introduction

Bighead carp (*Hypophthalmichthys nobilis*) and grass carp (*Ctenopharyngodon idella*) are Asian cyprinids that have been widely introduced outside their native range via unintentional escapes, biomanipulation programs, or for fishery enhancement (Kelly et al. 2011; Kolar et al. 2007). They are considered undesirable and detrimental invasive species in many parts of their introduced range (Azevedo-Santos et al. 2011; Boros et al. 2014; Conover et al. 2007; Xie and Chen 2001). These species have become especially problematic in North America (Conover et al. 2007), where they

are established throughout the central and southern portions of the Mississippi River Basin, and have been reported in 24 states and in Lake Erie (USGS 2018). The ecological consequences of this invasion have been the focus of much recent research. Documented effects include competition with native fishes (e.g., Irons et al. 2007; Wang et al. 2018) and wide-ranging examples of cascading ecological effects caused by overgrazing of submersed vegetation (Shireman and Smith 1981), depletion of plankton (Kolar et al. 2007), or increased bioturbation and nutrient resuspension (Rowe 1984).

Invading species are most easily eradicated or controlled if detected early (Hoffman et al. 2011; Simberloff et al. 2013), but locating and eradicating small numbers of aquatic invaders is extremely difficult. Recent research efforts on control methods have focused on removal methods, the effectiveness of which depends on precise identification and location of target fish (Asian Carp Regional Coordinating Committee 2014; Basler and Schramm 2006; MacNamara et al. 2016). For fish that aggregate in schools (or at least are likely to co-locate with or close to conspecifics), the relatively novel "Judas fish" technique has shown some promise. Judas fish are equipped with surgically implanted transmitters, and released in the wild to live up to their biblical namesake by betraying the locations of conspecifics. The technique has been employed successfully to locate and harvest aggregations of invasive common carp (*Cyprinus carpio*) in Tasmania (Patil et al. 2015) and in North America (Bajer et al. 2011). It has also been used to enhance harvest of lake trout (*Salvelinus namaycush*) where they are invasive, such as in Yellowstone Lake, Wyoming, USA, (Gresswell 2011). While those efforts have been successful in locating aggregations of fish in the wild, one drawback was that Judas fish were not always sterile, potentially adding to the invasion problem by reproducing if not recaptured. Furthermore, use of Judas fish might be better perceived by the public if the fish are sterile. The removal of all or part of the testes has been attempted unsuccessfully to create sterile grass carp (Clippinger and Osborne 1984; Underwood et al. 1986). Such surgical castration or use of genetically-sterile fish such as triploid fish (Malone 1984) might be a feasible option for use as Judas fish, but it is unknown whether such fish would have a reduced reproductive motivation, making them less likely to participate in spawning movements, and thus less likely to co-locate with conspecifics at critical times. An ideal Judas fish would be incapable of reproduction, but retain a similar reproductive motivation, so that it migrates, selects habitats, and behaves in the same way as a normal fertile fish.

We thus tested whether surgical ligation and division of the *ductus deferens* could effectively sterilize adult diploid bighead and grass carp, with the aim to keep the gonads (and thus reproductive motivation) intact while effectively blocking the reproductive potential. Albeit less than

common in ordinary veterinary sterilization, surgical ligation and division of the *ductus deferens* (akin to human vasectomy) is a relatively straightforward surgical procedure. Such surgically altered individuals could be subsequently implanted with transmitters and released to the wild to locate, and potentially remove, aggregations of conspecific invasive species, if sterility was retained for the life of the fish.

Materials and methods

Surgical ligation and division of the ductus deferens

Fish handling and euthanasia were performed according to relevant guidelines and regulations and the Columbia Environmental Research Center Animal Care and Use Policy. Experimental protocols were approved by the Columbia Environmental Research Center's Animal Care and Use Committee and this study was approved by the committee. The surgeon was a licensed veterinarian specializing in surgery, and was provided fresh cadavers upon which to practice before operating on live fish.

Ten bighead carp and nine grass carp were selected between July 2 and 24, 2014 from experimental ponds at the United States Geological Survey, Columbia Environmental Research Center, Missouri, USA. Each was surgically sterilized through ligation and division of the *ductus deferens*. Only male fish were selected for this procedure, based on external sexually dimorphic characters (i.e., pectoral fin ray morphology with raised rays on male bighead carp and rough rays in male grass carp). All fish used in the study were individually marked with passive integrated transponder (PIT) tags, by intramuscular insertion, near the dorsal fin.

Prior to surgery, fish were sedated using MS-222 (Syndel USA, Ferndale, WA, USA; 50–75 mg/L) in an aerated tank, and their total length measured. Once a surgical plane of anesthesia was achieved, the fish was placed in right lateral recumbence in a tilted trough that allowed continued submersion of the fish's head while the surgical site was elevated out of the water (Figures 1a and b). Scales were plucked from the caudolateral abdomen over the proposed incision site, which was over the course of the *ductus deferens*, estimated by tracing in a craniodorsal direction from the urogenital papilla. The skin was then aseptically prepared with 61% ethyl alcohol (Avagard D, 3M, St. Paul, MN). A single fenestrated water-impervious sterile drape was used to isolate the sterile field (Figure 1b). Then, an approximately 2.5 cm skin incision was made with a scalpel over the course of the *ductus deferens* (Figure 1c). The incision was deepened by incising the muscle until the body cavity was entered. Gelpi self-retaining retractors were used to maintain the surgical exposure (Figure 1d). The *ductus deferens* was identified by inserting an 8 French red rubber catheter (Feeding Tube and Urethral Catheter, Medtronic Covidien, Minneapolis, MN) into the urogenital pore. Once the catheter could be seen within the

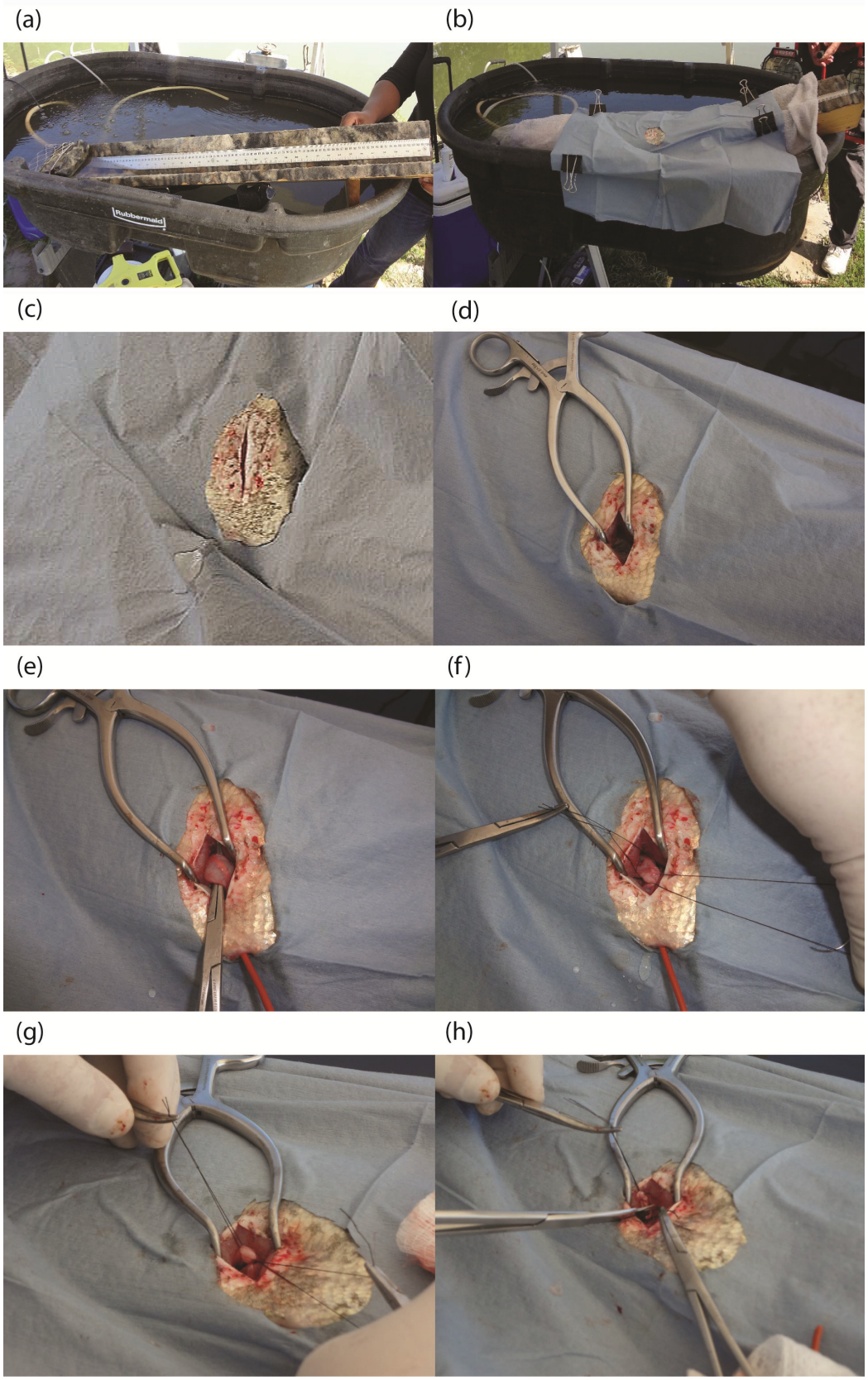

Figure 1. Surgical sterilization procedure using ligation and division of the *ductus deferens*. Tilted trough allowing continued submersion of the fish's head while the surgical site was elevated out of the water (a). Sterile field with a single fenestrated water-impervious sterile drape (b). Skin incision over the course of the *ductus deferens* (c). Surgical exposure through Gelpi self-retaining retractors (d). Dissection around the *ductus deferens* with right angle forceps (e) and passing of two strands of 3-0 silk around the structure (f). Separate ligation of the two silk strands (g), and transection of the *ductus deferens* with scissors between the two silk ligatures (h). Photographs by Tony Mann.

ductus deferens, a right angle forceps was used to dissect around the *ductus deferens* (Figure 1e) and pass two strands of 3-0 silk (Perma-hand Silk, Ethicon Inc., Somerville, NJ) around the structure, 5 to 15 mm apart (Figure 1f). The catheter was extracted, the two silk strands were tied separately (Figure 1g), and the *ductus deferens* was transected with scissors between the two silk ligatures (Figure 1h). The surgical wound was closed in one layer by using 3-0 poliglecaprone (Securocryl, Securos Surgical, Fiskdale, MA) in a simple continuous pattern in the skin. Time from the original incision to closing was recorded for each individual surgery. After surgery, the fish were transferred to a tank with saline (3.5 parts per thousand) aerated pond water and held overnight. The following day the saline pond water was replaced by fresh, flowing pond water. Twenty-four hours after surgery, the fish were checked for signs of infection or immediate mortality before releasing them back into a dedicated pond.

Fish rearing, control and euthanasia

Surgically sterilized carp were supplied daily with commercial fish feed pellets. Ponds were monitored daily for dead or moribund fish. The carp remained in the pond through the winter until the following reproductive season.

The pond was seined in early June 2015, 11 months after the surgery and near the beginning of the putative spawning season. Carp were inspected for flowing milt by compressing the abdominal cavity. Grass carp which did not produce milt at that time received an intramuscular dose of 3.3 mg/kg body weight of common carp pituitary extract (Stoller Fisheries, Spirit Lake, IA) and were examined for release of milt 24 hours later. Fish were then euthanized with an overdose of MS-222.

Postmortem analysis

Euthanized fish were measured, weighed and dissected to determine, where possible, the reasons for success or failure of the surgery. Postmortem analysis was carried out by inserting a cannula in the urogenital opening to verify the absence of a connection between the urogenital opening and the gonads. Further inspection involved the opening of the body cavity to visually inspect the ductus deferens for the presence of ligatures or recanalizations, as well as inspecting the gonad development.

Given the small sample size, non-parametric statistical tests (Mann-Whitney and Kolmogorov–Smirnov tests, for mean and shape of the distributions) were performed using PAST software (Hammer et al. 2001) to explore whether surgery time was related to fish mortality, success of the procedure, or different between the two species.

Table 1. Details of bighead and grass carp individuals subject to this trial.

Individual ID	Species	Surgery time (min)	Length at surgery (mm)	Final Length (mm)	Final Weight (g)	Milt present (Y/N)
BH1	Bighead carp	15	820		*Died after surgery*	
BH2	Bighead carp	17	830		*Died after surgery*	
BH3	Bighead carp	19	871	882	6520	Y
BH4	Bighead carp	14	870	899	6450	N
BH5	Bighead carp	20	910	920	8290	Y
BH6	Bighead carp	27	850	854	5950	Y
BH7	Bighead carp	18	810	810	6010	Y
BH8	Bighead carp	22	732	735	4520	Y
BH9	Bighead carp	20	863	884	6250	Y
BH10	Bighead carp	24	773	835	6710	Y
GC1	Grass carp	29	552	635	3180	Y
GC2	Grass carp	18	670	701	3800	Y
GC3	Grass carp	24	680	680	4080	N
GC4	Grass carp	17	565	660	4370	Y
GC5	Grass carp	22	710	720	4330	N
GC6	Grass carp	29	670	742	4580	N
GC7	Grass carp	16	472	548	2170	Y
GC8	Grass carp	20	580	635	3330	N
GC9	Grass carp	21	735	770	5400	N

Results

The average individual surgery time was 20.6 ± 4.4 minutes (19.6 ± 3.9 minutes for bighead carp and 21.8 ± 4.8 minutes for grass carp). The immediate mortality rate was 0, but two bighead carp died within 4 days after the surgery (overall 10.5% mortality, bighead carp specific 20%). The remaining surgically sterilized fish survived the ligation and division procedure, the observation period, and the following 11-month period of rearing.

Eleven months after the surgery, most fish had fully recovered, with a complete regeneration of the scales around the incision area, albeit one bighead carp individual (BH4) had an open wound at the surgery site and appeared to be in obvious distress. All but two fish (one bighead carp and one grass carp) increased in length during the study period.

Overall, surgical sterilization using ligation and separation of the *ductus deferens* was not effective in limiting the reproductive capabilities of either carp species. Eleven individuals (64.7% of the total that survived the procedure) had flowing milt upon postmortem inspection (Table 1). Of those with milt present, the duct had partially or completely recanalized (Figure 2), the sutures were encased in scar tissue, and the gonads were not atrophied. Recanalization apparently took several forms, sometimes in nearly the original position, sometimes in a circuitous route around or through scar tissue, and in other cases milt appeared to exit the body through the colon or bladder.

Only 6 fish (35.3% of the total that survived the procedure) did not have flowing milt (Table 1). One of these was the bighead carp with an open wound (BH4) and the others were all grass carp. Postmortem inspection of

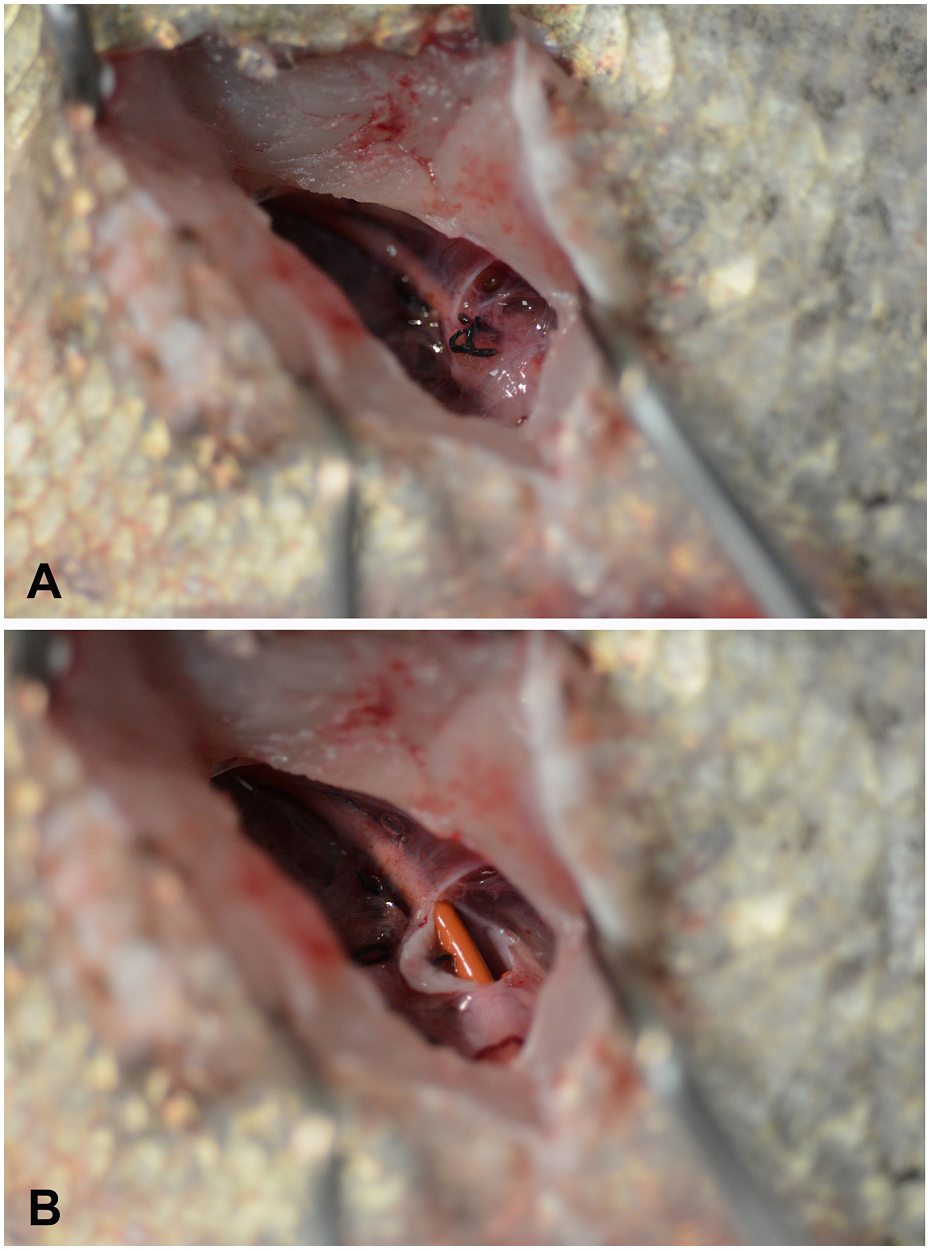

Figure 2. Recanalization of the ductus deferens. (A) red rubber catheter passing through the area adjacent to the suture. (B) New channel opened to illustrate the recanalization. Photographs by Tony Mann.

the bighead carp that did not produce milt revealed that the urinary bladder and the *ductus* were tightly adhered together, but we were unable to determine if recanalization to the urinary bladder was complete. In any case, the fish was ill due to the open wound, and testes were not in a condition to produce milt.

Grass carp which did not initially produce milt also did not produce milt after injection with carp pituitary extract, but one grass carp jumped from the tank between injection and the post-injection examination. That fish was partially eaten by an animal and so was not examined for post-injection milt production or postmortem examination. Postmortem dissection of remaining grass carp that did not exhibit milt showed that

they possessed mature testes, except one individual (GC8) that had developed a partial ovary and exhibited signs of an intersex condition, and might not have been capable of producing milt for that reason. At least two of the grass carp that did not produce milt had a *ductus deferens* that was almost completely recanalized. In one of these fish the end of the *ductus* was adhered to the urinary bladder adjacent to the vent, and in the other the two the severed ends of the *ductus* terminated very close together in a ball of scar tissue. In one fish, the *ductus* was adhered to the body wall, with no evidence that it was ready to recanalize.

There were no significant differences in surgery time between the two species (Mann-Whitney P = 0.35 and Kruskal-Wallis P = 0.88). There were also no significant differences in surgery time between bighead carp that died and all surviving fish (Mann-Whitney P = 0.08 and Kruskal-Wallis P = 0.08) or between the bighead carp that died and bighead carp that survived (Mann-Whitney P = 0.15 and Kruskal-Wallis P = 0.07).

Discussion

Ligation and separation of the *ductus deferens* proved ineffective for most fish; sterilization was not achieved, and individuals were potentially able to reproduce by the following spawning season. Of the six fish that did not produce milt, two had other reasons influencing their ability to produce milt (sickness and intersex), and two appeared close to *ductus deferens* recanalization. Thus, simple ligation and division of the *ductus deferens* does not seem to be a viable procedure to sterilize bighead carp or grass carp for deployment as Judas fish, if it is critical that individuals must remain sterile over a long term. Patil et al. (2014) attempted a similar ligation method to sterilize common carp; in that study, ten months after surgery, 77% of the surgically sterilized common carp did not produce milt when injected with Ovaprim to induce milt production. Those fish were then released as part of a Judas fish harvest operation, thus their longer-term continued sterility was not assessed.

We tested a surgical procedure to achieve fish sterilization and focused on males, rather than females, because the ductus deferens was a more robust and more distinct structure upon which to operate than was the oviduct. Surgical sterilization through the ligation and separation of the *ductus deferens* was a procedure with a low short-term mortality rate. Although there was no significant statistical difference in surgery times, it is worthwhile to note that short-term mortality occurred only in the first two individuals subjected to surgery. This suggests that short-term mortality in our study could be due to a "learning curve" related to the organization of the surgical team, the surgery itself, or the perioperative activities. Moreover, the intersex condition found in one of the grass carp individuals at culling cannot be attributed to the surgical procedure, as cases of natural intersex conditions are also reported in the wild (Papoulias et al. 2006).

Future trials should verify the effectiveness of existing surgical procedures, but could also explore new alternative techniques of surgical sterilization, such as blocking the duct with external structures (e.g., helix plugs or gluing agents) that would either block the flow of milt entirely or sterilize it when passing through. Chemically-induced sterilization might also be an effective alternative to surgical sterilization (Kutzler and Wood 2006; Rhodes 2017); calcium chloride injections have been successfully employed on rats, dogs and cats (Jana and Samanta 2007), and zinc gluconate has been successfully tested as an alternative to castration in dogs (Levy et al. 2008). Patil et al. (2014) attempted chemical sterilization of common carp using GnRH agonist implants, and were successful at temporarily reducing spermatocrit, but not successful at creating sterile male common carp for Judas fish applications.

In areas where fertile fish are highly abundant, it may be less important for Judas fish to be sterile, because their spawning potential may be insignificant in proportion to that of the extant population. In such cases Judas fish, regardless of fertility, could be useful to locate aggregations and improve the effectiveness of removal actions. However, Judas fish could be even more useful at the opposite end of the invasion spectrum, to detect invasive species in the early stages of invasion, when population densities are low and where a rapid response might be useful to eliminate fish before they begin to reproduce consistently (e.g., the case of Italy, Milardi et al. 2015, 2017), or when in the final stages of an eradication campaign, such as that for common carp in Tasmania (Patil et al. 2015). In such cases, where the contribution of the Judas fish to the available spawning stock might not be insignificant, a permanently sterile Judas fish is required.

In Minnesota, at the leading edge of the bighead carp invasion range and where bighead carp are very rare (USGS 2018), a fertile bighead carp was captured in 2017, implanted with an acoustic telemetry tag, and released (MNDNR 2018). In May 2018, while attempting to recapture the telemetered individual, Minnesota Department of Natural Resource personnel captured two additional large bighead carp. It is unlikely that these fish would have been captured without the use of the telemetered fish (MNDNR 2018). While anecdotal, these captures provide evidence that rare bighead carp might be captured through the use of the Judas fish technique. It represents a success because two fish were captured with the release of one fish and other fish may yet be captured. However, at the time of this writing, the telemetered fish itself has not yet been recaptured, illustrating the value of sterilization, if an adequate technique could be found. Ongoing invasive carp control efforts clearly indicate a need for methods to focus and maximize the effectiveness of control measures. The development of adequate sterilization techniques to create Judas fish could substantially improve the effectiveness of comprehensive control programs.

Acknowledgements

We thank Curt Byrd, Joe Deters, Dr. Janelle Francis, Brad Howell, Dr. James Klovstad, and Ben Stahlschmidt for assistance with fish husbandry and surgical procedures. We thank Aaron Delonay and two anonymous reviewers for their constructive comments reviews of the manuscript. Any use of trade, firm, or product names is for descriptive purposes only and does not imply endorsement by the U.S. Government.

References

Asian Carp Regional Coordinating Committee (2014) Monitoring and response plan for Asian carp in the upper Illinois River and Chicago Area Waterway system. Washington DC: ACRCC, Council on Environmental Quality, 200 pp

Bajer P, Chizinski CJ, Sorensen P (2011) Using the Judas technique to locate and remove wintertime aggregations of invasive common carp. *Fisheries Management and Ecology* 18: 497–505, https://doi.org/10.1111/j.1365-2400.2011.00805.x

Basler MC, Schramm HL (2006) Evaluation of electrofishing and fyke netting for collecting black carp in small ponds. *Transactions of the American Fisheries Society* 135: 281–287, https://doi.org/10.1577/T05-119.1

Boros G, Mozsár A, Vitál Z, Nagy A, Specziár A (2014) Growth and condition factor of hybrid (Bighead *Hypophthalmichthys nobilis* Richardson, 1845 × silver carp *H. molitrix* Valenciennes, 1844) Asian carps in the shallow, oligo-mesotrophic Lake Balaton. *Journal of Applied Ichthyology* 30: 546–548, https://doi.org/10.1111/jai.12325

Clippinger D, Osborne JA (1984) Surgical sterilization of grass carp, a nice idea. *Aquatics* 6: 9–1

Conover G, Simmonds R, Whalen M (2007) Management and control plan for bighead, black, grass, and silver carps in the United States Aquatic Nuisance Species Task Force, Asian Carp Working Group, Washington, DC. https://www.asiancarp.us/Documents/Carps_Management_Plan.pdf

Gresswell RE (2011) Biology, status, and management of the Yellowstone Cutthroat Trout North American Journal of Fisheries Management 31: 782–812

Hammer Ø, Harper D, Ryan P (2001) PAST: Paleontological statistics software package for education and data analysis vol 4. Palaeontologia Electronica, vol 1., 9 pp

Hoffman JC, Kelly JR, Trebitz AS, Peterson GS, West CW (2011) Effort and potential efficiencies for aquatic nonnative species early detection. *Canadian Journal of Fisheries and Aquatic Sciences* 68: 2064–2079, https://doi.org/10.1139/f2011-117

Irons KS, Sass GG, McClelland MA, Stafford JD (2007) Reduced condition factor of two native fish species coincident with invasion of non-native Asian carps in the Illinois River, U.S.A. Is this evidence for competition and reduced fitness? *Journal of Fish Biology* 71: 258–273, https://doi.org/10.1111/j.1095-8649.2007.01670.x

Jana K, Samanta PK (2007) Sterilization of male stray dogs with a single intratesticular injection of calcium chloride: a dose-dependent study. *Contraception* 75: 390–400, https://doi.org/10.1016/j.contraception.2007.01.022

Kelly AM, Engle CR, Armstrong ML, Freeze M, Mitchell AJ (2011) History of introductions and governmental involvement in promoting the use of grass, silver, and bighead carps. In: Chapman DC, Hoff MH (eds), Invasive Asian Carps in North America, AFS Symposium vol. 74. American Fisheries Society, Bethesda, Maryland, 265 pp

Kolar C, Chapman D, Courtenay Jr. W, Housel C, Williams J, DP J (2007) Bigheaded carps: a biological synopsis and risk assessment. American Fisheries Society, Bethesda, Maryland, 204 pp

Kutzler M, Wood A (2006) Non-surgical methods of contraception and sterilization. *Theriogenology* 66: 514–525, https://doi.org/10.1016/j.theriogenology.2006.04.014

Levy JK, Crawford PC, Appel LD, Clifford EL (2008) Comparison of intratesticular injection of zinc gluconate versus surgical castration to sterilize male dogs. *American Journal of Veterinary Research* 69: 140–143, https://doi.org/10.2460/ajvr.69.1.140

MacNamara R, Glover D, Garvey J, Bouska W, Irons K (2016) Bigheaded carps (*Hypophthalmichthys* spp.) at the edge of their invaded range: using hydroacoustics to assess population parameters and the efficacy of harvest as a control strategy in a large North American river. *Biological Invasions* 18: 3293–3307, https://doi.org/10.1007/s10530-016-1220-4

Malone JM (1984) Triploid white amur. *Fisheries* 9(2): 36

Milardi M, Lanzoni M, Kiljunen M, Torniainen J, Castaldelli G (2015) Natural recruitment contributes to high densities of grass carp *Ctenopharyngodon idella* (Valenciennes, 1844) in Western Europe. *Aquatic Invasions* 10: 439–448, https://doi.org/10.3391/ai.2015.10.4.07

Milardi M, Chapman D, Lanzoni M, Long JM, Castaldelli G (2017) First evidence of bighead carp wild recruitment in Western Europe, and its relation to hydrology and temperature. *PloS ONE* 12: e0189517, https://doi.org/10.1371/journal.pone.0189517

MNDNR (2018) Minnesota Department of Natural Resources press release. Tagged bighead carp leads DNR to 2 others in St. Croix River. http://news.dnr.state.mn.us/2018/05/17/tagged-bighead-carp-leads-dnr-to-2-others-in-st-croix-river/

Monteiro de Azevedo-Santos V, Magalhaes A, Rigolin-Sa O, Vitule J (2011) Registro de um grande exemplar de carpa-cabeçuda *Hypophthalmichthys nobilis* (Richardson, 1845) (Cypriniformes: Cyprinidae) no reservatório de Furnas, Minas Gerais, Brasil. In: Odila Rigolin de Sá (ed), Bacia Hidrográfica: Estudos do Rio Grande no Sudoeste de Minas Gerais. Brasil, 302 pp

Papoulias DM, Chapman DC, Tillitt DE (2006) Reproductive condition and occurrence of intersex in bighead carp and silver carp in the Missouri River. *Hydrobiologia* 571: 355–360

Patil JG, Purser G, Nicholson A (2014) Development and deployment of sterile 'Judas fish' to assist carp eradication in Lake Sorell, Tasmania-Surgical and chemical sterilization. Report number: FRDC 012/39 Inland Fisheries Service Tasmania and NCMCRS, University of Tasmania

Patil JG, Purser G, Nicholson A (2015) Sterile 'Judas' carp—Surgical sterilisation does not impair growth, endocrine and behavioural responses of male carp. *General and Comparative Endocrinology* 221: 173–182, https://doi.org/10.1016/j.ygcen.2015.03.005

Rhodes L (2017) New approaches to non-surgical sterilization for dogs and cats: Opportunities and challenges. *Reproduction in Domestic Animals* 52: 327–331, https://doi.org/10.1111/rda.12862

Rowe DK (1984) Some effects of eutrophication and the removal of aquatic plants by grass carp (*Ctenopharyngodon idella*) on rainbow trout (*Salmo gairdnerii*) in Lake Parkinson, New Zealand. *New Zealand Journal of Marine and Freshwater Research* 18: 115–127, https://doi.org/10.1080/00288330.1984.9516035

Shireman J, Smith CR (1981) Biological synopsis of grass carp (*Ctenopharyngodon idella*). Center for Aquatic Weesds, Gainesville, Florida, 52 pp

Simberloff D, Maris V, Martin J-L (2013) Inaction ≠ caution: response to Larson, Kueffer, and the ZiF Working Group on Ecological Novelty. *Trends in Ecology & Evolution* 28: 257, https://doi.org/10.1016/j.tree.2013.02.006

Underwood JL, Hestand III RS, Thompson BZ (1986) Gonad regeneration in grass carp following bilateral gonadectomy. *The Progressive Fish-Culturist* 48: 54–56, https://doi.org/10.1577/1548-8640(1986)48<54:GRIGCF>2.0.CO;2

USGS (2018) United States Geological Survey - Non-indigenous Aquatic Species Database. https://nas.er.usgs.gov/default.aspx (accessed May 19, 2018)

Wang J, Chapman D, Xu J, Wang Y, Gu B (2018) Isotope niche dimension and trophic overlap between bigheaded carps and native filter-feeding fish in the lower Missouri River, USA. *PloS ONE* 13: e0197584, https://doi.org/10.1371/journal.pone.0197584

Xie P, Chen Y (2001) Invasive carp in China's plateau lakes. *Science* 294: 999–1000, https://doi.org/10.1126/science.294.5544.999c